

## **V. Multi-Level Analysis of Cortical Neuroanatomy in Williams Syndrome**

**Albert M. Galaburda**

Beth Israel Deaconess Medical Center, Boston

**Ursula Bellugi**

The Salk Institute for Biological Studies

### **Abstract**

■ The purpose of a neuroanatomical analysis of Williams Syndrome (WMS) brains is to help bridge the knowledge of the genetics of this disorder with the knowledge on behavior. Here, we outline findings of cortical neuroanatomy at multiple levels. We describe the gross anatomy with respect to brain shape, cortical folding, and asymmetry. This, as with most neuroanatomical information available in the literature on anatomical–functional correlations, links up best to the behavioral profile. Then, we describe the cytoarchitectonic appearance of the cortex. Further, we report on some histometric results. Finally, we present findings of immunocytochemistry that attempt to link up to the genomic deletion. The gross anatomical findings consist mainly of a small brain that shows curtailment in the posterior-parietal and occipital regions. There is also subtle dysmorphism of cortical folding. A

consistent finding is a short central sulcus that does not become opercularized in the interhemispheric fissure, bringing attention to a possible developmental anomaly affecting the dorsal half of the hemispheres. There is also lack of asymmetry in the planum temporale. The cortical cytoarchitecture is relatively normal, with all sampled areas showing features typical of the region from which they are taken. Measurements in area 17 show increased cell size and decreased cell-packing density, which address the issue of possible abnormal connectivity. Immunostaining shows absence of elastin but normal staining for Lim-1 kinase, both of which are products of genes that are part of the deletion. Finally, one serially sectioned brain shows a fair amount of acquired pathology of microvascular origin related most likely to underlying hypertension and heart disease. ■

### **INTRODUCTION**

#### **Behavioral and Genetic Characteristics to be Explained by Neuroanatomy**

Williams Syndrome (WMS) provides a unique opportunity to study the brain in a condition where the genetic basis is understood and the cognitive profile is highly distinctive and well characterized, and may represent a prototype neurocognitive disorder for the study of the relationship between genes and behavior via the uncovering of the anatomical structures that intervene. The main idea is that complex behaviors, including cognitive and emotional behaviors, are implemented in large neural systems that are formed in part from genetic blueprints and in part through learning. Moreover, the reaction of the brain to the learning environment itself is partly controlled by genes.

The field of cognitive neuroscience thus far has been able to expand our knowledge about where different

neural systems are located in the brain and what types of mental activity activates or suppress these neural systems. This information, together with older information from the study of patients with neurological damage, have shown, for example, that the frontal lobes are involved in many aspects of working memory, and that the primary visual cortex participates in mental imagery. The systems in question are built from the bottom up through a sequence of timed molecular processes involving developmental genes, and the same structures are maintained and modified throughout life through the action of additional molecular events. Thus, a clinical condition affecting gene structure and function can be well placed to modify the building of cognitively relevant brain structures and their maintenance throughout life, which in turn can affect the behaviors that these structures support. Furthermore, behavior itself is capable of modifying the brain structures that support it. In this

sense, the structure of the brain lies between the genes involved in their development and maintenance and the behaviors they support and by which they are modified.

Anatomy is the logical link between genes and behavior. The purpose of our research on the neuroanatomy of WMS is to help link the anatomical findings to the genetic/molecular disorder on the one hand and to the behavior disorder on the other, thus helping to link genes to cognition and emotion. Specifically, an anatomical research program in WMS must ultimately be able to explain the relationship between the deleted genes in region 7q11.23 (Perez-Jurado et al., 1998; Osborne et al., 1997a, 1997b; Wang et al., 1997; see also Korenberg et al., 1996; Korenberg et al., 1997a; Korenberg, Chen, Mitchell, & Sun, 1997b; Korenberg et al., 1998; Korenberg et al., this volume) and the building and maintenance of brain structures on the one hand, and, on the other hand, the abnormal behaviors, consisting of mental retardation, visuo-spatial deficits, relatively good linguistic abilities, an unusual personality, and good facial recognition and musical abilities (Jones et al., this volume; Lenhof, Wang, Greenberg, & Bellugi, 1997; Bellugi, Klima, & Wang, 1996; Bellugi, Adolphs, Cassady, & Chiles, 1999a; Bellugi, Lai, & Korenberg, in press; Bellugi, Lichtenberger, Mills, Galaburda, & Korenberg, 1999b; Bellugi, Mills, Jernigan, Hickok, & Galaburda, 1999c; Bellugi, Lichtenberg, Jones, Lai, & St. George, this volume).

Of great importance to the understanding of the general biology of WMS are the findings of distinctive facial features and cardiovascular defects, which typically include supra-aortic stenosis or pulmonic stenosis, calcium metabolism abnormalities, failure to thrive in infancy, and delayed development. Genetic diagnosis is now possible, and, in almost all individuals clinically identified with WMS, it has been found that there is a hemizygous deletion of one copy of the elastin gene and adjacent genes (Lowery et al., 1995; Ewart et al., 1993). Other genes involved in the deletion, in most cases, include Lim-1 kinase, RF2c, FZD3, and syntaxin 1A (see Korenberg et al., this volume; Perez-Jurado et al., 1998; Osborne et al., 1997a, 1997b; Wang et al., 1997).

Just as neuroanatomy is placed somewhere between gene expression and behavior, so is neurophysiology. Some relevant neurophysiologic findings, therefore, will be reviewed. Thus, a series of studies has been undertaken using event-related potential techniques (ERPs) to assess the timing and organization of neural systems that are active during sensory, cognitive, and language processing in WMS subjects (Mills, 1998; Mills et al., this volume; Neville, Mills, & Bellugi, 1995). Two of the notable characteristics of the WMS behavioral profile have so far been investigated. First, the auditory recovery cycle has been tested for indices of hyperexcitability at any stage along the auditory pathway that might provide clues to the basis of the sensitivity to auditory stimuli shown by many WMS subjects. Second, auditory sentence processing, which includes semantic anoma-

lies has been assessed as to whether such processing is mediated in WMS by the same pathways that are active in normal age-matched controls. Auditory brainstem evoked responses turn out to be normal in WMS subjects, indicating that auditory hyperexcitability does not occur at the brainstem level. However, data from an auditory recovery paradigm suggest a possible cortical mechanism; WMS subjects are indistinguishable from normal controls on a visual recovery paradigm. Taken together, these studies suggest that the hyperacusis observed in WMS may be mediated by hyperexcitability specifically within the cortical areas that are utilized in processing acoustic information. Guided by this finding, Hickok and collaborators found that Heschl's gyrus may be larger in WMS (Bellugi et al., 1999b; Hickok et al., 1995).

ERPs have also been recorded of WMS subjects' responses to auditorily presented words in sentences (Mills, Neville, Appelbaum, Prat, & Bellugi, 1997). One half of the sentences were highly contextually constrained, ending with a semantically appropriate word, whereas the other half ended with an anomalous word (e.g., "I take my coffee with cream and paper."). Previous research has shown that normal subjects indicate a large negative response at 400 msec (N400) to semantically unprimed words, and this is considered as an index of how the mental lexicon is organized. WMS subjects displayed responses that were highly abnormal within the first 200–300 msec following word onset. The abnormality consisted of a large positivity, not seen in normal control subjects at any age. This effect, only apparent over temporal brain regions, may relate to WMS hyperacusis. The effect of the semantic anomaly is larger over the left hemisphere in WMS than in the controls, which may be related to the unusual semantic proclivities shown by WMS subjects in certain tasks (Bellugi et al., 1996; Bellugi et al., 1999b). Moreover, the WMS responses did not show the expected left-hemisphere asymmetries for grammatical function words that are typical for normal children and adults, suggesting that there may be an unusual pattern of brain organization underlying the WMS language capacities.

From the point of view of the neuroanatomy of WMS, these behavioral characteristics conjure up a variety of dichotomies: (1) Involvement of parietal vs. frontal areas; (2) Involvement of right-hemisphere vs. left-hemisphere structures; (3) Involvement of dorsal streams (sometimes clumped together with magnocellular streams [see Atkinson et al., 1997], as opposed to the ventral [parvocellular] streams) and, finally, (4) Involvement of cortical vs. subcortical anatomical systems.

New techniques of brain imaging permit visualization and analysis of structures within the brain that were not possible in the past. Techniques developed, e.g., by Frank, Damasio, and Grabowski (1997) (also, see Reiss et al., this volume), now permit an unprecedented visualization and three-dimensional analysis of the living

brain of subjects. Initial studies revealed that both WMS and DNS leave a distinctive morphological stamp on specific brain regions. Past MRI studies of brain volumes were performed on a group of matched adolescents and young adults with WMS and DNS (Bellugi, Hickok, Lai, & Jernigan, 1997; Jernigan & Bellugi, 1990, 1994). Neuro-morphological characterization of WMS vs. DNS subjects by magnetic resonance imaging showed that the cerebral volume in both groups was smaller than that of age-matched normal controls. Analyses revealed important regional differences in brain volume between the two groups of subjects. First, anterior-brain volume was found to be disproportionately reduced in DNS subjects but proportionately preserved in subjects with WMS. Secondly, limbic structures in the temporal lobe showed essentially equal volumes in WMS and control subjects, but were significantly reduced in DNS subjects. On the other hand, the volume of the thalamus and lenticular nuclei were seen to be much better preserved in subjects with DNS than those with WMS. We also found that the anterior parts of the corpus callosum, like the anterior hemispheres, were preserved in WMS subjects, but diminished in DNS subjects (Wang, Doherty, Hesselink, & Bellugi, 1992).

Quantitative analysis of cerebellar volumes also suggested differences with cerebellar volume well preserved in WMS subjects but diminished in DNS subjects. Closer regional analyses were enlightening: Jernigan and Bellugi (1994) found that the locus of preservation in WMS was the neocerebellum. Of the two parts of the neocerebellum that were subjected to analysis, the neocerebellar vermis and the neocerebellar tonsils both showed volumetric preservation or even *increases* in WMS as compared to controls, whereas, both were found to be volumetrically diminished in DNS. Importantly, the specific regions of the neocerebellum that may be enlarged in WMS were shown to be dysplastic in autism (Jones, Lai, & Bellugi, 1999; Jernigan, Wang, & Bellugi, 1995; Courchesne, Yeung-Courchesne, Press, Hesselink, & Jernigan, 1988; Courchesne, Bellugi, & Singer, 1995).

More recently, Reiss et al. (this volume) carried out MRI studies with higher resolution techniques. In 14 young adult subjects with WMS and an aged-matched control group, the decreased in total brain volume was confirmed, as well as the relative preservation of the cerebellum. The superior-temporal gyrus was also found to be relatively preserved, an area that contains the auditory system and those auditory association areas that form part of language networks. There was also a significant curtailment of the volume of the brainstem. A greater ration of frontal to parieto-occipital forebrain volume was also found, and there was reduction of the forebrain white matter, with relative preservation of the cerebrocortical volume. Nonetheless, regionally, the right-occipital lobe showed excessive volume loss.

Results of related research suggest that the expansive prefrontal cortex and the neocerebellum, both selec-

tively (relatively) preserved in WMS, are thought to be closely related. These two regions of the brain are most highly developed in *Homo sapiens*, and are thought to have evolved contemporaneously (Deacon, 1990). Furthermore, the neocerebellum has more extensive connections to prefrontal and other association areas of the cortex than do the older parts of the cerebellum. On the other hand, the reduction in the forebrain white matter may explain the curtailment of the brainstem, but it may be relevant to note that FZD3, which is one of the deleted genes, is associated with hindbrain segmentation, which could also explain, in part, the brainstem changes in WMS. Thus, the neuroanatomic profile of WMS emerging from neuroimaging is beginning to contribute to the understanding of the brain's organization by exhibiting a morphological pattern that can result from genetic bias. The finding that frontal and neocerebellar regions are selectively preserved in WMS suggests that they all may come under the influence of a single genetic, developmental factor, or that their development is mutually interactive, or both (Bellugi et al., 1999c). These issues bearing on the relationship of brain to behavior are fundamental to central questions of cognitive neuroscience.

## RESULTS

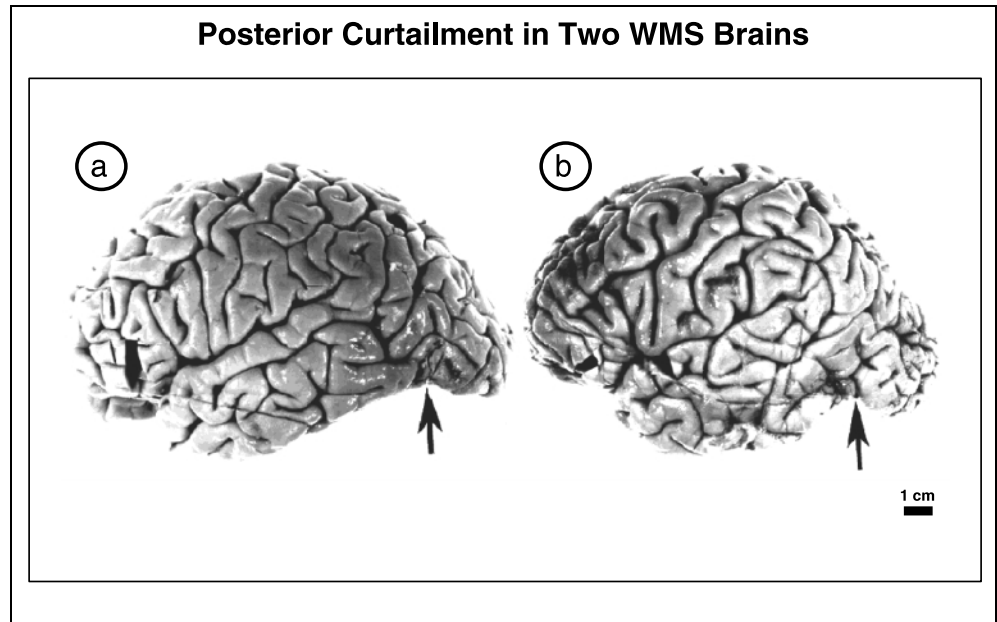
### Gross Anatomical Observations on Autopsy Specimens

The findings reported below are based on the study of four WMS brains from patients diagnosed in life on the basis of the typical somatic phenotype as well as genetic testing. The gross anatomical findings may be summarized as follows.

#### *Brain Weight and Shape*

Brain weight and shape are variable, but mostly we have seen small brains with parietal and occipital hypoplasia (Figure 1). The brain weight hovers around 800–1000 g, which is roughly in the order of the brain weights of patients with DNS. The shape, however, is different. In DNS, there is an antero-posterior curtailment of the brain, whereas this brachycephaly is not seen in WMS. Instead, the brain appears rather curtailed from top to bottom, especially in the posterior portions of the hemispheres. One of the specimens that we examined showed a striking top to bottom curtailment of the occipito-parietal regions on both hemispheres (Galaburda, Wang, Bellugi, & Rossen, 1994), which was not observed in the other three specimens, at least not to the same degree; but see Figure 1, which shows a clear but less dramatic curtailment in two specimens. There may also be modifications of the standard patterns of brain asymmetry that involve the planum temporale and the occipital lobe.

**Figure 1.** The arrows point to a marked indentation of the temporoparietal region in the area of the temporoparietal sulcus. However, note that the whole posterior-parietal and occipital regions are small.



*Cortical Folding and Asymmetry*

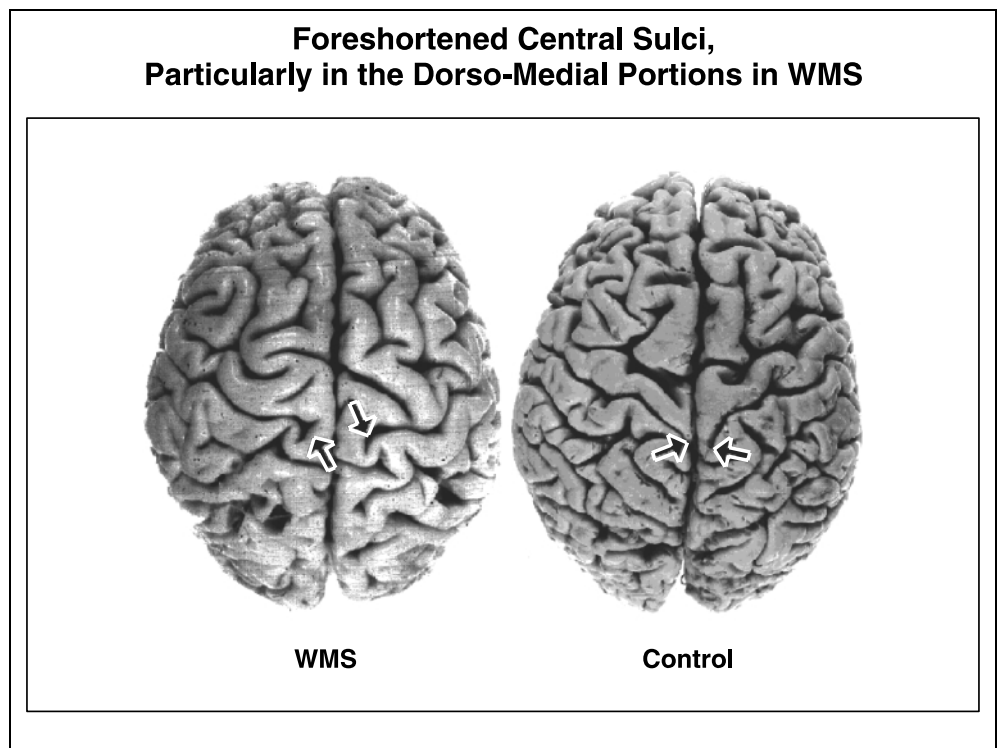
We have looked for anomalous gyri and found these to be variable. There is, however, a frequent finding of anomalous sulci in the dorsomedial portions of the hemispheres. A consistent finding in all four cases studied is made in the central sulcus. Unlike control brains, where the central sulcus reaches the interhemispheric fissure and proceeds a variable distance along the medial surface of the hemisphere in a characteristic posteriorly curved direction, the central sulcus in the

WMS brains ends substantially before it reaches the midline (Figure 2). We are now looking at this region in larger numbers of WMS subjects on MRI images in collaboration with Allen Reiss (Reiss et al., this volume).


*Reduced Volume of Amygdala*

We were able to examine one of the specimens for morphology of the amygdalar nuclei. The overall volume of the amygdala was diminished in the WMS specimen,

**Figure 2.** Note the difference in the medial reach (arrows) of the central sulci between the WMS and Control subjects, particularly in the dorsomedial portions of the hemispheres.



**Figure 3.** Amygdalar nuclei in WMS and normal brains, showing that in WMS the dorsal portion of the lateral nucleus (LNd) appears to be reduced and has an unusual shape. The arrow indicates a curtailment in the lateral nucleus of the amygdala. In this specimen, the nucleus was estimated to be about half the size of the average amygdala in normal subjects. Also, note that in the temporal horn (TH) is placed more dorsally in WMS individuals than in normal subjects.



and was estimated to be about half the size of the average amygdala in controls. Also, note that the temporal horn (TH) is more dorsally placed in WMS. Furthermore, there was an unusual scooping out of the nucleus in the region of the dorsal portion of the lateral subnucleus of the amygdala. This nucleus receives connections from visual association cortex (Figure 3). Of course, it would be premature to make too much of this finding in a single brain. However, if the finding is consistent among WMS brains, one would be prone to attempt a connection between this finding and the lack of stranger shyness in this group also characterized as hypersociability (Jones et al., this volume; Bellugi et al., 1999a). Thus, if visual and auditory experience does not acquire the proper emotional valence via the amygdalar circuit, the ancient way to avoid danger may be lost (Damasio, 1994).

*Parenchymal Softenings, Meningeal, Vascular, and other Neuropathological Findings Notably Absent*

In view of the commonly found cardiac and vascular pathology in WMS, we searched for evidence of vascular injury to the brain, presumably acquired during life and not resulting directly from genetic errors. We found none. In general, the cortex was intact, the blood vessels at the base of the brain and on the convexity were normal for age, and the meninges showed no evidence of previous bleeding.

**Architectonic Observations**

We examined blocks of tissue selected from most classes of cortex for architectonic differentiation. The architec-

tonic level of analysis refers to the anatomical level smaller than gyri and sulci (gross), but larger than the level of single cells (histological). This level permits analysis of the laminar and columnar arrangement of neurons and glia, myelin content, and vascularization, which under normal conditions shows remarkable regional differentiation based on proportions of large and small neurons, thickness of layers, presence or absence of columns, and other related features. This level of analysis has led to cortical architectonic maps such as those of Brodmann, von Economo and Koskinas, and others. The architectonic differentiation reflects, in part, cortical differentiation in connectivity and physiological properties of individual neurons comprising the areas. The architectonic findings may be summarized as follows.

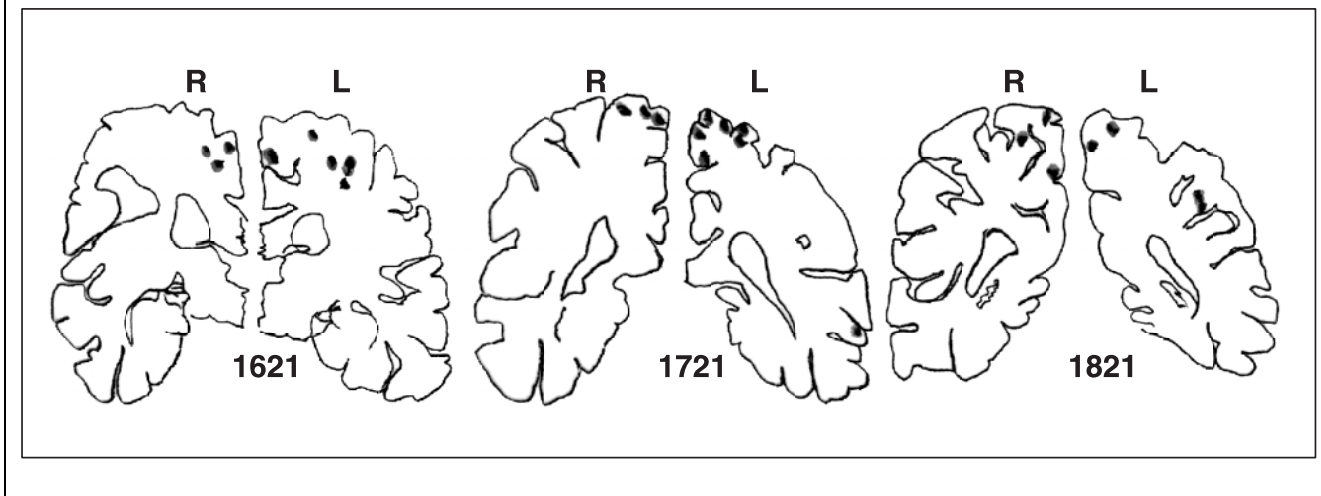
*Areas*

All areas sampled appeared relatively normal and recognizable according to established criteria for identification of architectonic areas. Thus, we noted well-differentiated primary cortices such as areas 4, 17, and 42, visual and auditory, respectively, first belt of association cortices such as areas 6, 18, and 22, and so-called integration or high-order association cortices, such as areas 37, 39, and 9 (all listed in the Brodmann nomenclature). This is compatible with the finding of relatively normal gyral folding, which reflects at least in part architectonic differentiation of the cortex.

*Increased Cell-Packing Density in Cortex*

We noted a tendency, albeit not uniform, for the cortex to show increased cell-packing density, coarseness of

## Microvascular Lesions in WMS, Primarily in Dorsal, Parietal and Occipital Lobes



**Figure 4.** Serial sections taken from WMS-3 showing microvascular lesions mainly in the dorsal-parietal and occipital lobes. Numbers refer to the section number; R=right hemisphere; L=left hemisphere.

neurons, and mild dysplastic features (Galaburda et al., 1994)—but see the histometric studies below for a more detailed analysis.

### *No Systematic Bias Affecting Architecture*

In view of the question regarding the intactness or lack thereof of the dorsoventral (magnocellular/parvocellular) dichotomy (see above), we looked for a systematic bias possibly affecting the architecture of dorsal parietal regions. We found none. There were also no other biases (e.g., frontal vs. parietal, left vs. right hemisphere). We cannot comment on the cortical vs. subcortical dichotomy based on the available material, including the amygdala.

One of our autopsy cases was processed in whole-brain coronal sections rather than in blocks of tissue, thus allowing a more thorough survey of the architectonic areas. While surveying this case, we noted neuropathological changes not of the developmental, but rather of the acquired cortical injury type, which had not been evident on the gross examination of this brain (see above). Thus, we saw evidence of microvascular pathology affecting the cortex of predominantly the dorsal hemispheres, parietal more than frontal (Figure 4). These consisted of gliotic small infarcts within the cortical ribbon and outside in the cortical subcortical junction. All of these lesions were well healed and could not be dated other than to say that they were at least a few months old. Stains for myelin aimed at determining whether the lesions leading to these scars took place within the first year or two of life were negative, thus indicating that the injury was not likely to have been perinatal. However, the location of these scars with respect to the dorsoventral dichotomy raised questions as to their connec-

tion with the behavioral profile of patients with WMS. For one, it raised the previously not considered possibility that the cognitive profile might also be related to acquired as well as genetic brain abnormalities.

### **Histometric Observations**

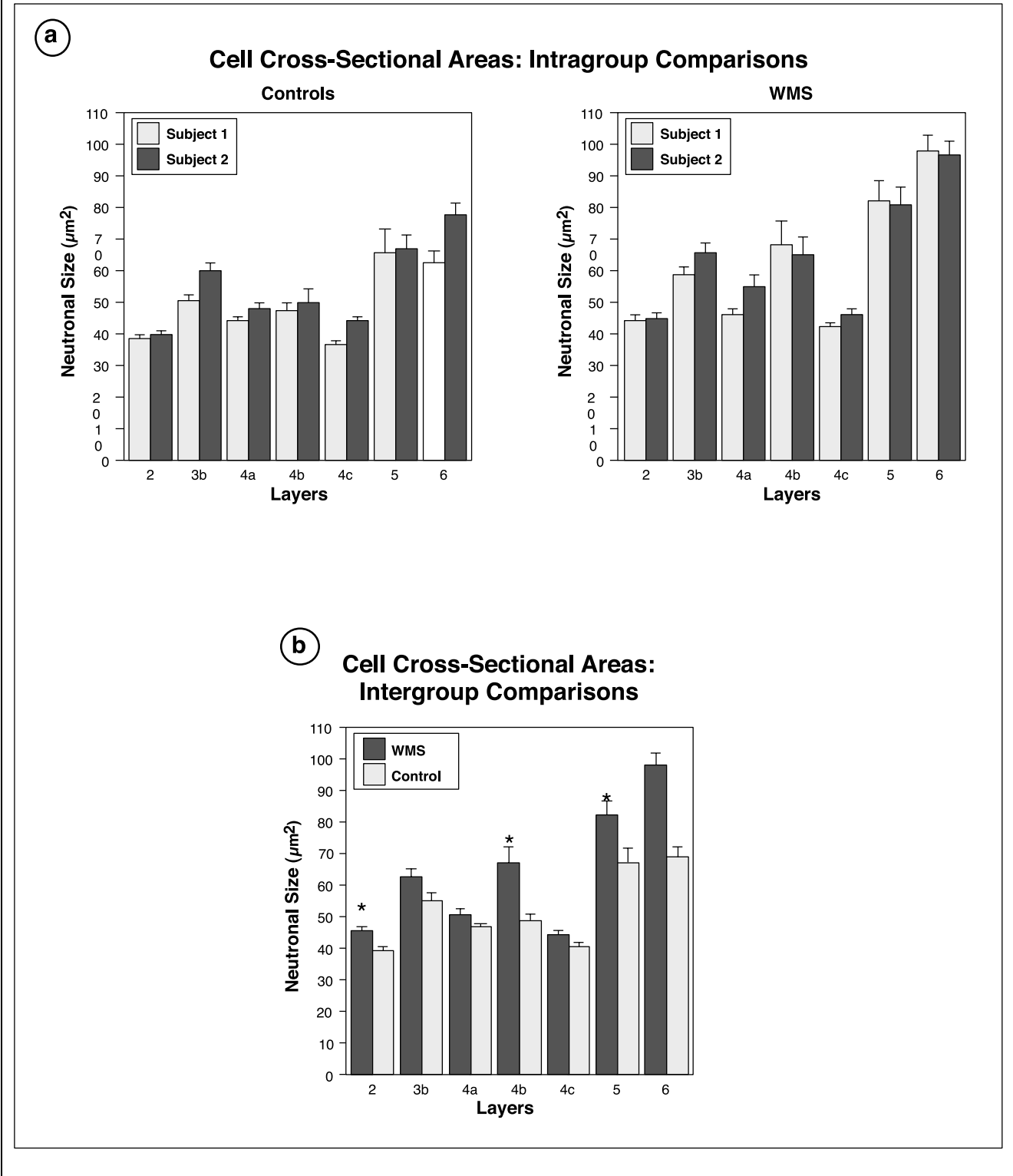
At the level of histological analysis, i.e., of single neurons, as at higher and lower levels, it is possible also to make quantitative statements such as density and size of neurons (histometric). This is an important step beyond architectonic analysis to document and expand on information gleaned at that level as well as for search for subtler changes that may not be obvious at the architectonic level. We are currently carrying out an extensive histometric analysis of theoretically relevant architectonic areas in WMS and report here on preliminary findings. These findings may be summarized as follows.

### *Increased Neuronal Sizes with Some Laminar Specificity*

There is not much variability within each layer, in spite of the fact that outlier neurons have not been deleted. Also, there is not much variability between subjects within each condition. WMS and control brains are compared directly in Figure 5a and b.

A repeated-measures ANOVA on these data are performed in Table 1 indicating the following: (1) There is almost a significance for Group for the statement “WMS have larger neurons than controls”; (2) There is a highly significant layer effect (i.e., cell size differs significantly from layer to layer, irrespective of experiment group). Of course, we would expect different cell sizes for neurons in different layers, as this is one of

## Increased Neuronal Sizes in WMS (Area 17-Primary Visual Cortex)

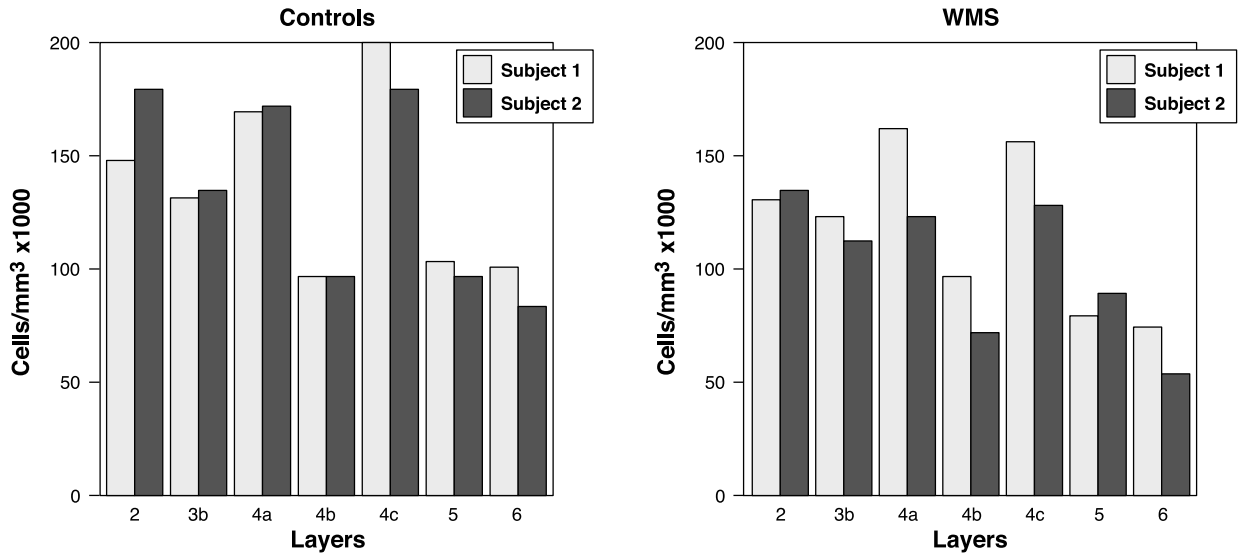


**Figure 5.** (a) Cell cross-sectional areas: Intragroup comparisons. Increased neuronal sizes with some laminar specificity. Although outlier neurons have not been deleted, there is not much variability in each layer. For instance, layer 4b and layer 5 contain Meynert stellates and pyramids that are much larger than surrounding cells, but which are few in numbers. These are kept in for the analysis. (b) Cell cross-sectional areas: Intergroup comparisons. Asterisks mark those layers in the figure where the differences are statistically significant. Layer 6 is close to significant, but the lack of significance probably reflects the variability between the two control subjects in that layer.

## Decreased Cell Packing Densities in WMS (Area 17-Primary Visual Cortex)

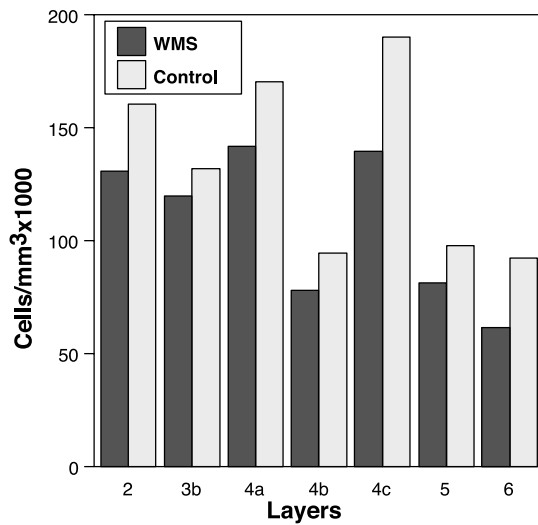
(a)

### Cell Packing Densities: Intragroup Comparisons



(b)

### Cell Packing Densities: Intergroup Comparisons



**Figure 6.** (a) Cell-packing densities: Intragroup comparisons. Decreased cell packing densities with no laminar specificity. (b) Cell-packing densities: Intergroup comparisons. Decreased cell-packing densities with no laminar specificity.

**Table 1.** ANOVA Table for Increased Neuronal Size (Layers)

	<i>df</i>	<i>Sum of squares</i>	<i>Mean square</i>	<i>F-value</i>	<i>P-value</i>
Group	1	958.526	958.526	13.368	.0673
Subject (Group)	2	143.409	71.705		
Layers	6	6213.781	1035.630	82.320	<.0001
Layers×Group	6	500.047	83.341	6.625	.0028
Layers×Subject (Group)	12	150.967	12.581		

the criteria used for dividing the cortical plate into layers; and (3) There is a significant interaction between layer and experimental group. This indicates that there are differences between WMS and controls in some layers but not others.

#### *Decreased Cell Packing Densities with No Clear Laminar Specificity*

The variability in the controls seems very small compared to that in the WMS cases (Figure 6a and b). In the latter, the variability is relatively high in layers 4 and 6, but much less in other layers. It is not clear what this means, but it will be important to follow this feature in the remainder of the histomorphometric studies, since increased variability in neuronal sizes in particular layers may indicate disturbance in neuronal migration. An ANOVA confirmed that there are no significant differences for cell-packing density other than those that can be attributed to laminar differences. A direct comparison was made for cell-packing density between WMS and controls. None of the differences in cell-packing density evident on the graph approached significance. A repeated-measures ANOVA suggests, however, that there is at least a trend toward controls having more cells than WMS. The data are summarized in Table 2 where the *F* value for Group approaches significance. This is due to the fact that for all layers, the cell-packing density for controls is greater than that for WMS. Again, this is not significant, but it will be followed in subsequent studies.

**Table 2.** ANOVA Table for Decreased Cell-Packing Densities (Layers)

	<i>df</i>	<i>Sum of squares</i>	<i>Mean square</i>	<i>F-value</i>	<i>P-value</i>
Group	1	4540384104.143	4540384104.143	10.882	.0809
Subject (Group)	2	834448884.143	417224442.071		
Layers	6	30936621404.214	5156103567.369	33.315	<.0001
Layers×Group	6	946343226.357	157723871.060	1.019	.4579
Layers×Subject (Group)	12	1857224352.857	154768696.071		

## **Molecular Observations**

As genes relating to the WMS deletions are just being discovered, it has been difficult to obtain specific antibodies and mRNA probes that react with human autopsy tissue. It is also worth remembering that with a hemideletion, the assumption, unless the function of the remaining allele is removed through imprinting, is that some gene function remains. In some cases, this gene function may be sufficient to code for detectable product. In others, there may be a threshold effect, with an all-or-none behavior. Barring technical problems, which abound in this area of research, lack of staining indicates that no gene function exists, whereas, positive staining does not address the issue of quantitative adequacy of gene function. The findings thus far, however, may be summarized as follows.

### *Elastin*

Elastin does not stain in forebrain neurons or glia, and is only found in blood vessels and meninges in normal forebrain. In the cerebellum, however, elastin stains normally in Purkinje cells and in mouse elastin messenger RNA is demonstrated in Purkinje neurons by in situ hybridization (Sawchenko, Dargusch, Arias, & Bellugi, 1997). The normal control cerebellum showed the immunostaining for elastin in Purkinje neurons, whereas the WMS brain did not (Figure 7).

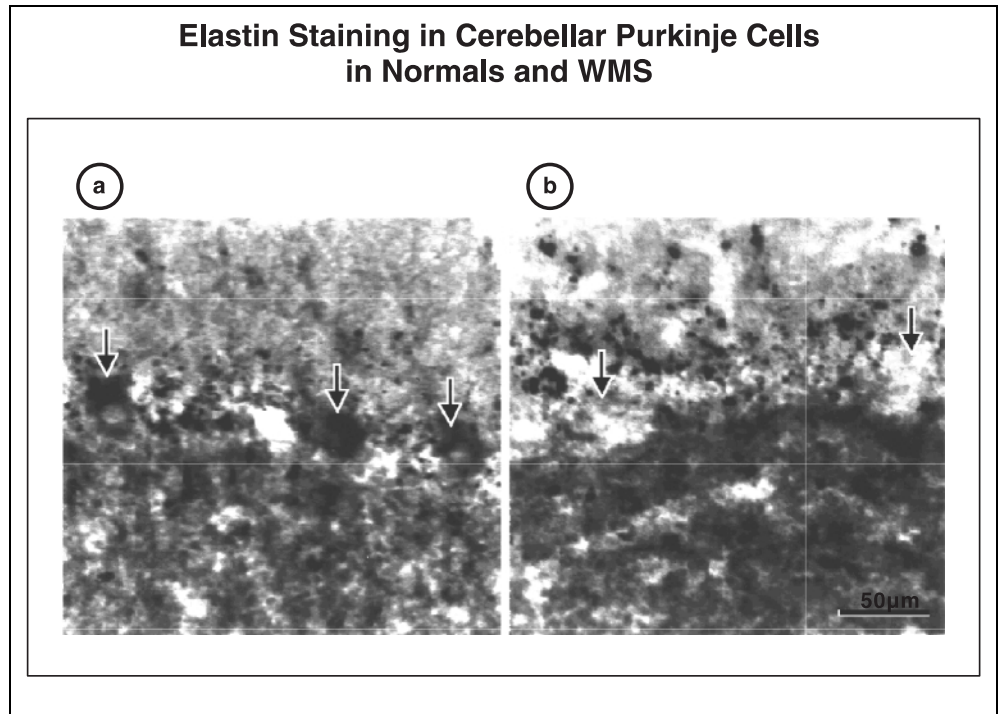
### *Lim-1 Kinase*

Lim-1 kinase appears to stain many forebrain neurons in normal human brain. Likewise, and unlike elastin, there is probably normal staining for Lim-1 kinase in the WMS cerebral cortex (Figure 8).

## **Detailed Studies**

Of the four WMS brain specimens, only one was processed in whole-brain serial sections and all are blocked for architectonic analysis. Blocks were taken of the dorsolateral- and ventrolateral-prefrontal cortex, superior- and inferior-parietal lobules, dorsal- and ventral-preoccipital cortex, superior-temporal gyrus, Heschl's

**Figure 7.** (a) Cerebellar Purkinje cells showing positive immunostaining for elastin Normals (arrows); (b) Arrows point to areas occupied by Purkinje cells in WMS-1, which do not stain for elastin.

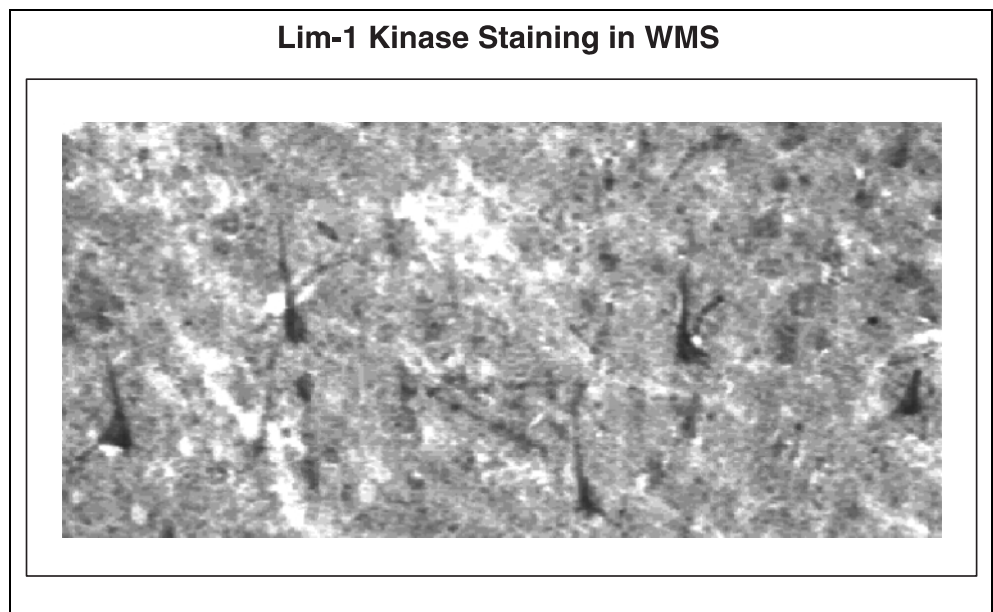


auditory gyrus, and calcarine cortex. The blocks were embedded in celloidin, which provides the best medium for Nissl staining. Nissl staining was accomplished with cresyl violet, which endows the cells with a purplish blue color of uniform intensity and suitable for histometric studies (see below). The architecture of a given region is analyzed under low power light microscopy with regards to several classic architectonic parameters: Overall cortical thickness, relative thickness of the laminae, impression of the cell-packing density of the cortex as a whole, general comparisons in this parameter between supra-

and infra-granular layers, and the cell-packing density (CPD) of individual layers, a sense of coarseness or fineness of the cellular panorama, which is determined by the relative sizes of the neurons comprising the layers, the way in which one layer is defined from its neighbors or melds with them, the way in which layer 6 neurons border with the subcortical white matter.

The prefrontal cortices are relatively thick, relatively sparsely celled, but more densely packed in the infra- than in the supra-granular layers, containing relatively coarse pyramidal neurons. Although the granule cell

**Figure 8.** Immunostain disclosing positive neurons in the cerebral cortex of WMS for Lim-1 kinase. This is a hemideleted gene that still expresses in WMS-3 in contrast to elastin, which does not (see Figure 7 for comparison).



layers are evident, they are never as richly packed as in the more posterior cortices of the temporal and parietal lobes. Laminar distinctiveness is not nearly as explicit as in the parietal cortices, and this is particularly true in the inferior-prefrontal cortices, which are more granular than the dorsal-prefrontal cortex, and where the granular layers blur the borders among the adjacent layers. All of these features are well developed in the frontal cortices in WMS. In general, there is the impression of increased cell-packing density, a feature that has been reported by us previously. As will be seen below when the histometric findings are reported and discussed, it turns out that this impression of increased cell-packing density is the result of increased glial cells, which under the low-power magnification used for architectonic analysis cannot be distinguished from small granular neurons. In the brain processed in serial histological sections, a previously unpredicted set of abnormalities was seen in the frontal lobe, which will be discussed below.

The parietal cortices are the most distinctively laminated in the brain, short of the primary visual cortex, and the dorsal-parietal cortex is even more so because of their relative hypogranularity compared to the ventral-parietal cortices. Granular neurons in layers 2 and 4 tend to blur laminar borders and render the overall impression of the cortex less laminated. Furthermore, the dorsal-parietal cortices show a distinct clearing of the region deep to layer 3c, adding to the layered appearance of the cortex. In general, because of decreased granularity and coarser pyramidal neurons, the dorsal-parietal cortices are coarser than the cortices of the inferior-parietal lobule. Special attention was paid to the architecture of the dorsal-parietal cortices in WMS, because this area is implicated in the behavioral abnormalities, either because of its contribution to the magnocellular visual system, or because of its known role in the performance of visuo-spatial tasks. However, no obvious architectonic distortion could be seen in these areas in WMS other than those that appear to characterize the cortex of WMS in general: An impression of increased cell-packing density and greater coarseness of the cellular architecture. In the frontal lobe, where the cortex is naturally coarse, this feature was less obvious; but, in the parietal cortex, the coarseness in WMS is more easily perceived under low-power magnification. In the brain processed in serial histological sections, a previously unpredicted set of abnormalities was seen in the parietal lobe, which will be discussed below.

The occipital cortices are similar in appearance to the parietal cortices, except for the primary visual cortex, area 17, which contains a highly differentiated layer 4 with three sublaminae—a, b, and c (a and b). The temporal cortices also resemble the parietal cortices in that layer 4 is well formed. There are differences between the cortical areas covering the superior and the middle- and inferior-temporal gyri, with the latter having

a more ribbon-like appearance of layer 4, and the former being among the more granular of all sensory related cortices. The WMS cortical areas were examined with the above criteria in mind, and no significant abnormalities are noted in any of the samples taken.

### *Case Studies*

Our first case was a patient with WMS who died of cardiac complications of the disease at age 31 years (see Galaburda et al., 1994). The gross morphology of the brain was abnormal in that the parietal regions are reduced dramatically in size in comparison to the frontal regions, a finding that did not reproduce in any of the following cases to the same degree. The presplenial portion of the corpus callosum was thinned, as was the case in WMS-2-94, but not so in the other two cases. Cytoarchitectonic abnormalities were found throughout the cortex and consisted of primitive layering similar to that found in brains 1–2 years of age; these, however, were subtle in nature, and the normal variability in this feature is not well understood. Histological findings were of two types: There was increased cell-packing density, as compared to an age-matched control brain; neurons were often found in clusters in abnormal position and location, including excessive Cajal–Retzius cells in the molecular layer and clusters of subcortical neurons. The capillaries of the cortex displayed a primitive morphology, and we saw several subcortical arterioles surrounded by inflammatory cells. Areas of abnormal gyral formation did not show especially different microscopic anomalies, and in this one specimen, we could not ascertain a rostro-caudal gradient in malformation to match the gross anatomical finding of relative sparing of the frontal portions of the forebrain. We searched for, but did not find, nodular heterotopias, microgyria, pachygyria, porencephaly, ulegyria, or other similarly severe examples of developmental malformation.

Our second case was that of an 8-month-old baby who died of SIDS. The brain was harvested fresh rather than fixed. The gyral pattern appeared normal, but in retrospect, the dorsomedial portions of the hemispheres may be abnormal. The presplenial area of the corpus callosum was thinned, as in the other case. Some of the histological sections are examined and showed increased cell-packing density, although controls in this age group still need to be examined. Immunostains for AchE, CAT-301, laminin, CGRP, and elastin were run. AchE and laminin stained well. CGRP may be expressed excessively, but this needs confirmation against age-matched controls. CAT-301, which relates mostly to the magnocellular visual pathway, is found normally. Elastin did not stain in this brain. In an older control brain, elastin was seen in blood vessel walls (the tropoelastin form present intracellularly). The significance of these findings awaits stains of control tissue.

Our third case was that of a 53-year-old woman who died of cardiac failure. The diagnosis of WMS was not made until she was 39 years of age, but was extensively tested by our collaborators at The Salk Institute. A general postmortem examination was not done, but the brain was donated directly to this laboratory. The brain weight was 900 g, which is small. The cortical folding appeared normal, and there was lack of asymmetry of the planum temporale as well as reversed petalia in the frontal and occipital ends. Cytoarchitecture was normal, without apparent increase in cell-packing density, but still showing somewhat coarse neurons. Again, the architecture of representative areas of the frontal, parietal, occipital, and temporal lobes was basically normal in that no areas are found to be missing and the appearance of the areas was standard according to cytoarchitectonic criteria. However, this method allowed for the discovery of an unpredicted finding: There was evidence throughout the telencephalon, but most strikingly in the dorsal portions of the hemispheres, and more so in the parietal than in the frontal cortices, of a multiplicity of microvascular infarcts with gliosis and neuronal loss (see Figure 4). There had been no history of strokes during life, but we would suggest that the heart disease that is part of WMS may be associated with showers of emboli that produce microinfarcts in the dorsal borderzone vascular territories. Of importance to the present research is the realization that at least, in part, the behavioral picture in WMS may be the result of acquired brain damage through vascular injury and not only the genetic defect. Certainly, the predominant involvement of the dorsal portions of the brain, back more so than front, is compatible with a behavioral profile of visuo-spatial dysfunction and attentional deficits, with sparing of facial recognition and language. Unfortunately, the only certain way to check whether this finding is consistent across cases is by whole-brain serial section processing, which is expensive and time-consuming. We are also looking for ways by which the pathology described above can be demonstrated by magnetic resonance imaging during life, but this appears unlikely by virtue of the small size of the individual infarcts and their presence almost entirely intracortically, where imaging artifacts are more common and issues of contrast sensitivity play a larger role in visualization.

An important caveat of the interpretation that the acquired cortical lesions in this case may be related to the apparently dorsal parieto-occipital profile of WMS cognitive dysfunction, is the possibility that the vascular pathology may exist without the cognitive profile. This is because it appears to be the case that individuals with just the elastin gene deletion, who have heart disease but no cognitive defects, are equally likely to have the embolic disorder. It is still possible, however, that the behavioral picture is the result of a combination of acquired and developmental changes in the brain, and

that either alone may produce a much more subtle clinical picture. We are of course interested in processing a brain of pure elastin gene deletion from a behaviorally tested subject to expand our knowledge on this question, but admittedly this specimen will be difficult to locate.

Our fourth case came from a 46-year-old woman who died of metastatic breast carcinoma. During life, her brain had been imaged by our collaborators at The Salk Institute. The fixed brain was small, weighing only 1000 g. The cortical folding was relatively normal, but for bilaterally small superior-parietal lobules, symmetry of the planum temporale, and reversed frontal petalia. As with the other cases, there was the abnormal morphology of the superior-central region and the short central sulcus bilaterally. The cytoarchitecture of the selected blocks was normal, except for the appearance of increased cell-packing density and somewhat coarse neurons. The brain was chosen for histometric analysis because of the availability of an age- and gender-matched control. The results of the histometric analysis are presented above. In addition (see Figures 6 and 7), brain sections were immunostained for elastin and Lim-1 kinase. Whereas the latter was demonstrated in forebrain cortical neurons, elastin did not stain in WMS cerebellum but did stain in control Purkinje neurons.

#### *Histomorphometric Results*

Results are available for two WMS and two control brains in the primary visual cortex. Several hundred neurons were measured and counted in each specimen under  $40\times$  oil-immersion magnification with the aid of a computer-assisted morphometric analysis system. Cells are counted inside optical boxes, which provides a reliable measure of cell-packing density. Cell-packing density does not directly address the question of cell numbers. In general, with a brain of equivalent size, increased cell-packing density would indicate increased numbers of neurons and vice versa. With a smaller brain, which is the case in WMS, increased cell-packing density could signify increased numbers of neurons, no change in the number of neurons, or even decreased numbers of neurons depending on how much smaller the brain is and how much greater the cell-packing density. Decreased cell-packing density or no change in cell-packing density from controls, in WMS, would definitely indicate smaller numbers of neurons overall. It should be noted that three out of the four WMS brains examined under low-power light microscopy for cytoarchitectonics showed what appeared to be increased cell-packing density. This finding has not been confirmed in the histomorphometric analysis, thus far. In fact, if anything, the cell-packing density is diminished in WMS. We can account for this by the observation that glial nuclei cannot be distinguished from small granular neurons

under the low-power microscopy needed for cytoarchitectonics. However, under oil immersion, this distinction is easy and many of the cells that may have contributed to the impression of high cell-packing density under low power turned out to be glia instead. This finding illustrates the need to carry out high-magnification histometric analysis and the value of multilevel neuroanatomical study. If additional studies confirm the finding of lowered cell-packing density in WMS, this, coupled with a smaller brain, would indicate that the total number of neurons is decreased in WMS. The finding of larger neurons and decreased numbers of neurons would also suggest a changed pattern of connectivity, particularly if the numbers of neurons is not diminished in subcortical areas. Thus, a preservation of subcortical structures and a diminution of cortical neurons is compatible with greater numbers of cortico-subcortical connections per individual cortical neuron, which would explain their increased size. It behooves us now to look at subcortical cell-packing density in WMS as an partial test of this hypothesis.

Molecular events observed through immunostaining for specific gene products showed that all antibodies assayed for—including laminin, acetylcholinesterase, the CAT-301 marker for the magnocellular visual pathway, and CGRP—reacted positively to the antibodies. A monoclonal antibody to tropoelastin, the intracellular form of elastin, was applied to the forebrain and cerebellum. Elastin in the forebrain was only demonstrated in blood vessels. On the other hand, Purkinje neurons are stained by the monoclonal antibody to elastin in control but not WMS cerebella. This is in spite of the fact that the deletion is hemizygous, such that there might be some production of tropoelastin. At this point, it appears that there is a threshold effect, which is not reached by virtue of the existence of the hemideletion. On the other hand, we have been able to stain WMS brain with an antibody for Lim-1 kinase, which is another gene known to be part of the hemideletion. The immunostain demonstrates cortical neurons in the forebrain, and both WMS and control brains show rich staining. Regarding elastin staining, it is thought that this matrix protein may alter neuronogenesis and neurite growth in developing brain. Elastin does not appear in glia or neurons of the forebrain in the mature state. On the other hand, elastin could be present in the matrix of forebrain structures during critical developmental periods, which has not been studied so far. Elastin is expressed in adult cerebellar Purkinje cells, and its absence in WMS may help predict for (1) local cerebellar changes in WMS and (2) alteration of fronto-cerebellar circuitries involved in behaviors such as language, motor control, and eye movements. Future research will be aimed at examining the distribution of elastin related changes in cerebellum and in forebrain areas connected with these cerebellar regions. If materials become available, addi-

tional observations may be made during development of fronto-cerebellar connections.

Ongoing work addresses expression of RF2c, FZD3, so-called “frizzled” gene, and syntaxin 1A, which are also included in the deletion. In view of the findings described thus far, it will be important not only to specify activity or lack thereof of these molecules in WMS tissue, but also to discover regional difference in expression between dorsal and ventral forebrain structures, frontal and parieto-occipital regions. An additional contrast between cortical and subcortical expression, with attention paid to the amygdala, is also important to search for.

### Summary

The gross anatomical findings can be summarized as follows: The overall shape of the brain has not proven to be consistently abnormal. Although the first brain received showed a strong reduction in the posterior half of the forebrain, and both the first and second brains showed thinning of the preoccipital portion of the corpus callosum, the remainder of the brains, albeit small, exhibit a relatively normal configuration. An exception may be found in the occipital pole, where two other brains showed curtailment. So far, the most consistent gross neuroanatomical finding is the abnormal length of the central sulcus, whereby the fissure does not follow its normal course dorsomedial to end on the interhemispheric surface of the hemisphere, but rather ends short 1 or 2 cm lateral to the interhemispheric fissure. This produces an unusual configuration of the dorsal-central region, including the dorsal portions of the superior-parietal lobule and the dorsal-frontal gyrus. Of interest is the fact that it is exactly these regions that are implicated in the abnormal behavior demonstrated by patients with WMS. It should be added that the gyral markings are inconsistently anomalous, often demonstrating unusual number and configuration of gyri on the medial posterior surface of the hemispheres and on the temporal lobes. One case, that of an 11-month-old male, showed clumps of anomalous gyri giving the impression of micropolygyria (but not showing the architectonic changes associated with that malformation). Finally, there is a suggestion that brain asymmetry, as far as the planum temporale and lobar petalias, may be anomalous in this condition.

The cytoarchitecture of the cortical areas comprising the WMS forebrain appears to be mostly normal. Subtle dysplastic changes have been noted, which, however, are not easily quantifiable or compared to control brains. In general, the cortical areas examined are normal in appearance and appropriate for the place from which the blocks are taken. An impression of increased cell-packing density under low-power magnification turned out not to persist after histomorphometric analysis, which revealed that, if at all, there was diminished cell-

packing density in the cortex of WMS. An additional morphometric finding was that the average size of cortical neurons, as measured in area 17, was greater in WMS than in control brains. Coupled with normal or decreased cell-packing density, this could mean increased subcortical connectivity in these brains.

Acquired neuropathologic findings are seen in one of the cases, which was processed in whole-brain serial sections. These are consistent with microinfarcts—probably reflecting underlying heart disease and embolus formation—and affected dorsal portions of the hemispheres. The affected areas are known to mediate visuo-spatial and attentional tasks. Finally, the products of some of the deleted genes have been screened for in WMS. Elastin does not stain in the cerebellum in WMS, despite the preservation of one elastin gene in the hemideletion. Lim-1 kinase, on the other hand, another hemideleted gene, stains normally in cortical neurons in WMS.

## DISCUSSION

The link between anatomy and behavior appears to fit a dorsoventral (magno-parvo) dichotomy, rather than a fronto-caudal, left-right, or even a cortico-subcortical dichotomy. It is hypothesized that further analysis of MRI data with this idea in mind will disclose particular involvement of the dorsal portions of the hemispheres, both frontal and parieto-occipital. The behavioral profile indicates preservation of some but not all language functions, compatible with perisylvian language areas, which belong to the ventral system. Likewise, not all visual functions are impaired, with striking preservation of face recognition, a ventral function, in the face of striking visuo-spatial impairment, a dorsal function. Of additional interest is the possible involvement of the amygdalar visually related lateral nucleus, which may explain the lack of appropriate fear associated with new faces, even potentially threatening faces, in these subjects. Since this portion of the amygdala also receives auditory projections, one could predict that the WMS subjects may not be normally sensitive to threatening voice and speech. Much more work will be needed to further document these hypotheses, particularly the finding of more evidence supporting involvement of dorsal regions at architectonic and histometric levels, with sparing of ventral regions at these levels.

The link to the genes from the anatomy is still lacking, but amenable to discovery, as more genes with brain developmental effects are identified in the deletion. The trick is to be certain that the functional integrity or absence thereof is demonstrable during early development, at a time when the neural systems are being built, and that the purported dysfunction remains and interferes with further neural plasticity during learning and growth. Moreover, a stronger support of the dorsoven-

tral hypothesis will be obtained if we are able to show that at least at some point during development, the affected genes are expressed more or less in the dorsal than in the ventral regions of the brain. The demonstration that one or more genes involved in the hemideletion are expressed in dorsal regions and not in ventral regions and maintain expression throughout life will go a long way in helping establish a link between behavior and genes in WMS. During the course of discovery, however, other, perhaps more interesting, possibilities may become evident.

## Acknowledgments

The research was supported by a grant from the National Institute of Child Health and Human Development (P01 HD33113 to U. Bellugi). The authors thank the regional and national Williams Syndrome Associations and the families who assisted with these studies.

Reprint requests should be sent to A. Galaburda, Neurology Unit, K-4, Dana 711, Beth Israel Deaconess Medical Center, 330 Brookline Avenue, Boston, MA, 02215.

## REFERENCES

- Atkinson, J., King, J., Braddick, O., Nokes, L., Anker, S., & Braddick, F. (1997). A specific deficit of dorsal stream function in Williams syndrome. *NeuroReport*, 8, 1919–1922.
- Bellugi, U., Adolphs, R., Cassady, C., & Chiles, M. (1999a). An experimental investigation of hypersociability in Williams syndrome. *NeuroReport*, 10, 1–5.
- Bellugi, U., Hickok, G., Lai, Z. C., & Jernigan, T. (1997). Links between brain & behavior: Clues to the neurobiology of Williams syndrome. *International Behavioral Neuroscience Society Abstracts*, 6, 57.
- Bellugi, U., Klima, E. S., & Wang, P. P. (1996). Cognitive and neural development: Clues from genetically based syndromes. In D. Magnussen (Ed.), *The life-span development of individuals: Behavioral, neurobiological, and psychosocial perspectives* (pp. 223–243). The Nobel Symposium. New York: Cambridge University Press.
- Bellugi, U., Lai, Z. C., & Korenberg, J. (In Press). Genes, brains and behavior: What genetic disorders reveal about behavior. In E. Bizzi, P. Calissano, & V. Volterra (Eds.), *Frontiers of Biology Vol 4: The Brain of Homo Sapiens*. Rome, Italy: Istituto della Enciclopedia Italiana.
- Bellugi, U., Lichtenberger, L., Jones, W., Lai, Z., & St. George, M. (this volume). The neurocognitive profile of Williams syndrome: A complex pattern of strengths and weaknesses.
- Bellugi, U., Lichtenberger, L., Mills, D., Galaburda, A., & Korenberg, J.R. (1999b). Bridging cognition, the brain and molecular genetics: Evidence from Williams syndrome. *Trends in Neurosciences*, 5, 197–207.
- Bellugi, U., Mills, D., Jernigan, T., Hickok, G., & Galaburda, A. (1999c). Linking cognition, brain structure and brain function in Williams syndrome. In H. Tager-Flusberg (Ed.), *Neurodevelopmental disorders: Contributions to a new framework from the cognitive neurosciences* (pp. 111–139). Cambridge, MA: MIT Press.
- Courchesne, E., Bellugi, U., & Singer, N. (1995). Infantile autism and Williams syndrome: Social and neural worlds apart. Special Issue, *Genetic Counseling*, 6, 144–145.
- Courchesne, E., Yeung-Courchesne, R., Press, G. A., Hesselink, J. R., Jernigan, T. L. (1988). Hypoplasia of cerebellar vermal

- lobules VI and VII in autism. *New England Journal of Medicine*, 318, 1349–1354.
- Damasio, A. R. (1994). *Descartes' error: Emotion, reason, and the human brain*. New York: G.P. Putnam's Sons.
- Deacon, T. W. (1990). Rethinking mammalian brain evolution. *American Zoology*, 30, 629–705.
- Ewart, A. K., Morris, C. A., Atkinson, D., Jin, W., Sternes, K., Spallone, P., Stock, A. D., Leppert, M., & Keating, M. T. (1993). Hemizyosity at the elastin locus in the developmental disorder, Williams syndrome. *Nature Genetics*, 5, 11–18.
- Frank, R. J., Damasio, H., & Grabowski, T. J. (1997). Brainvox: An interactive, multimodal visualization and analysis system for neuroanatomical imaging. *Neuroimage*, 5, 13–30.
- Galaburda, A., Wang, P. P., Bellugi, U., & Rossen, M. (1994). Cytoarchitectonic anomalies in a genetically based disorder: Williams syndrome. *NeuroReport*, 5, 757–758.
- Hickok, G., Neville, H., Mills, D., Jones, W., Rossen, M., & Bellugi, U. (1995). Electrophysiological and quantitative MR analysis of the cortical auditory system in Williams syndrome. *Cognitive Neuroscience Society Abstracts*, 2, 66.
- Jernigan, T. L., & Bellugi, U. (1990). Anomalous brain morphology on magnetic resonance images in Williams syndrome and Down syndrome. *Archives of Neurology*, 47, 529–533.
- Jernigan, T. L., & Bellugi, U. (1994). Neuroanatomical distinctions between Williams and Down syndromes. In S. Broman & J. Grafman (Eds.), *Atypical cognitive deficits in developmental disorders: Implications for brain function* (pp. 57–66). Hillsdale, NJ: Erlbaum.
- Jernigan, T. L., Wang, P. P., & Bellugi, U. (1995). Neuromorphological characteristics of Williams syndrome. Special Issue, *Genetic Counseling*, 6, 145–146.
- Jones, W., Bellugi, U., Lai, Z., Chiles, M., Reilly, J., Lincoln, A., & Adolphs, R. (this volume). Hypersociability in Williams syndrome.
- Jones, W., Lai, Z. L., & Bellugi, U. (February, 1999). Relations between cerebellar vermal areas and neuropsychological performance in Williams syndrome. *Journal of the International Neuropsychological Society*, 5, 152.
- Korenberg, J., Chen, X. -N., Hirota, H., Lai, Z., Bellugi, U., Burian, D., Roe, B., & Matsoka, R. (this volume). Genome structure and cognitive map of Williams syndrome.
- Korenberg, J. R., Chen, X. -N., Lai, Z., Yimlamai, D., Bisighini, R., & Bellugi, U. (1997a). Williams syndrome: The search for the genetic origins of cognition. *American Journal of Human Genetics*, 61, 103.
- Korenberg, J. R., Chen, X. -N., Mitchell, S., & Sun, Z. -G. (1997b). The genomic organization of Williams syndrome. *International Behavioral Neuroscience Society Abstracts*, 6, 59.
- Korenberg, J. R., Chen, X. -N., Mitchell, S., Sun, Z. -G., Hubert, R., Vataru, E. S., & Bellugi, U. (1996). The genomic organization of Williams syndrome. *American Society for Human Genetics Supplement*, 59, A304.
- Korenberg, J. R., Hirota, H., Chen, X. -N., Lai, Z., Yimlamai, D., Matsuoka, R., & Bellugi, U. (1998). *The molecular genetic basis of Williams syndrome*. Presentation in symposium, Bridging cognition, brain and gene: Evidence from Williams syndrome. Abstract, Cognitive Neuroscience Society 1998 Annual Meeting Abstract Program, 11.
- Lenhoff, H. M., Wang, P. P., Greenberg, F., & Bellugi, U. (1997). Williams syndrome and the brain. *Scientific American*, 277, 68–73.
- Lowery, M., Morris, C., Ewart, A., Brothman, L., Zhu, X., Leonard, C., Carey, J., Keating, M., & Rothman, A. (1995). Strong correlations of elastin deletions, detected by FISH, with Williams syndrome: Evaluation of 235 patients. *American Journal of Human Genetics*, 57, 49–53.
- Mills, D. L. (1998). *Electrophysiological markers for Williams syndrome*. Presentation in symposium, Bridging cognition, brain and gene: Evidence from Williams syndrome. Abstract, Cognitive Neuroscience Society 1998 Annual Meeting Abstract Program, 10.
- Mills, D., Alvarez, T., St. George, M., Applebaum, L., Bellugi, U., & Neville, H. (this volume). Electrophysiological studies of face processing in Williams syndrome.
- Mills, D., Neville, H., Appelbaum, G., Prat, C., & Bellugi, U. (1997). Electrophysiological markers of Williams syndrome. *International Behavioral Neuroscience Society Abstracts*, 6, 59.
- Neville, H., Mills, D., & Bellugi, U. (1995). Functional brain organization in Williams syndrome. Abstract, Special Issue, *Genetic Counseling*, 6, 141–142.
- Osborne, L. R., Herbrick, J., Greavette, T., Heng, H. H. Q., Tsui, L. -C., & Scherer, S. (1997a). PM52-related genes flank the rearrangement breakpoints associated with Williams syndrome and other diseases on human chromosome 7. *Genomics*, 45, 402–406.
- Osborne, L. R., Sodar, S., Shi, X. -M., Pober, B., Costa, T., Scherer, S. W., & Tsui, L. -C. (1997b). Hemizygous deletion of the syntaxin 1A gene in individuals with Williams syndrome. *American Journal of Human Genetics*, 61, 449–452.
- Perez-Jurado, L. A., Wang, Y. K., Peoples, R., Coloma, A., Cruces, J., & Francke, U. (1998). A duplicated gene in the breakpoint regions of the 7q11.23 Williams-Beuren syndrome deletion encodes the initiator binding protein TFII-I and BAP-135, a phosphorylation target of BTK. *Human Molecular Genetics*, 7, 325–334.
- Reiss, A., Eliez, S., Schmitt, J. E., Strous, E., Lai, Z., Jones, W., & Bellugi, U. (this volume). Neuroanatomy of Williams syndrome: A high-resolution MRI study.
- Sawchenko, P., Dargusch, R., Arias, C., & Bellugi, U. (1997). Evidence for elastin expression in cerebellar Purkinje cells: Implications for Williams syndrome. *International Behavioral Neuroscience Society Abstracts*, 6, 59.
- Wang, P. P., Doherty, S. D., Hesselink, J. R., & Bellugi, U. (1992). Callosal morphology concurs with neurobehavioral and neuropathological findings in two neurodevelopmental disorders. *Archives of Neurology*, 49, 407–411.
- Wang, Y. K., Samos, C. H., Peoples, R., Perez-Jurado, L. A., Nusse, R., & Francke, U. (1997). A novel human homologue of the *Drosophila* frizzled wnt receptor gene binds wingless protein and is in the Williams syndrome deletion at 7q11.23. *Human Molecular Genetics*, 6, 465–472.